

# ORTHOPEDICS

## today

CURRENT NEWS IN MUSCULOSKELETAL HEALTH & DISEASE

A SLACK Incorporated® publication

## Ankle arthritis patients see improvement in outcomes scores with Ilizarov fixator

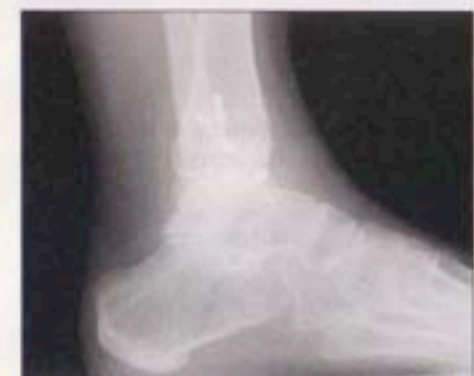Patients also maintained a preoperative range of motion found to be 'reasonable' before fixation.

by Tina DiMarcantonio  
ORTHOPEDICS TODAY STAFF WRITER

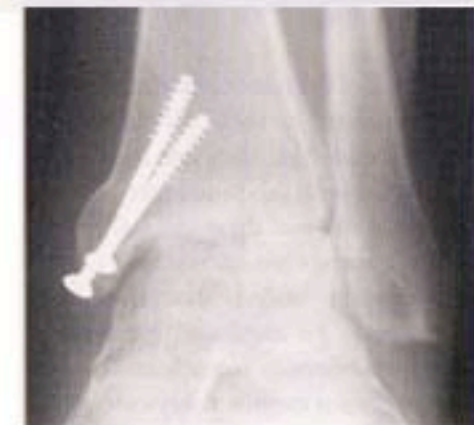TORONTO – Patients who underwent ankle distraction with an Ilizarov frame significantly improved in outcomes scores and successfully delayed fusion at a minimum of 1-year follow-up, in a retrospective study presented here.

S. Robert Rozbruch, MD, and his colleagues evaluated this distraction technique in 25 patients with severe ankle osteoarthritis.

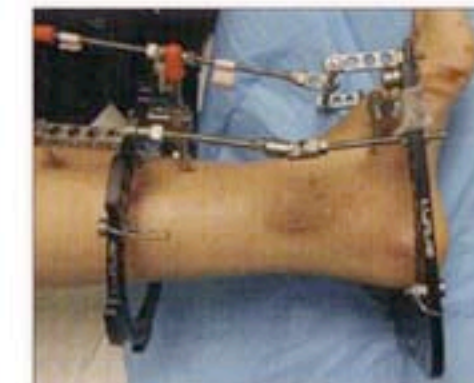
"There seems to be a need for a joint preservation procedure in a patient who has reasonable range of motion of



This 18-year-old woman presented with post-traumatic avascular necrosis; joint space narrowing is apparent. Images: Rozbruch SR



In the same patient, from the talar side osteonecrosis is evident.



Rozbruch and his colleagues applied ankle joint distraction with the Ilizarov external fixator.

the ankle with end-stage arthritis," Rozbruch said at the American Orthopaedic Foot and Ankle Society (AOFAS) 23rd Annual Summer Meeting.

"There is some scientific background

for this technique, and it is based on the concept that cartilage can regenerate. There have been a number of basic science studies that have shown this."

### Device maintains mobility

The investigators' goal was to create an environment where damaged articular cartilage is mechanically

unloaded through distraction and intermittent hydrostatic pressure, Rozbruch said. "This was accomplished by walking on the frame, and also moving the ankle and maintaining range of motion," he said.

The circular external fixator allows distraction across the ankle, but also allows mobilization in the ankle joint by the placement of a hinge through the Inman axis. Surgeons also encourage weight-bearing in the device, Rozbruch said.

He and his colleagues obtained complete data for 23 patients. Patients

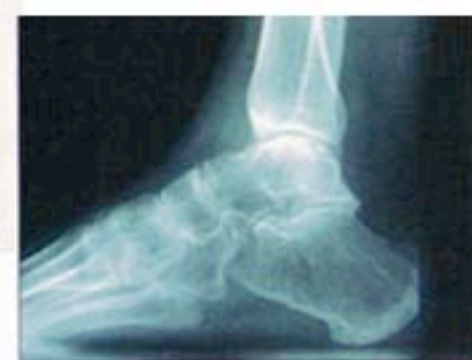(Fixator, continued on page 72)

## Fixator

(continued from page 71)

were an average 37.5 years old; there were 16 men and seven women in the study. Patients underwent ankle joint distraction for 10 weeks to 12 weeks and investigators performed follow-up at 1 year to 5 years, Rozbruch said.

Patients also underwent a number of adjuvant procedures, including four ankle arthroscopies, one ankle arthrotomy, six supramalleolar osteotomies and five Achilles tendon releases, Rozbruch said.



Here is the patient 2 years after wearing the Ilizarov fixator.



"Our impression is that these clinical results, in fact, improve over time."

— S. Robert Rozbruch, MD

### Unclear repair mechanism

The patients' AOFAS scores improved from a mean 55.05 preoperatively to 74.81 postoperatively, which was statistically significant, he said.

Investigators also found that pa-

tients maintained their preoperative ankle range of motion. The mean dorsiflexion was 7.2° at preop and 4.3° postoperatively; plantar flexion changed from 32.4° to 33.8°.

"We were able to correct the equines contractures in four patients, improving their arc of motion," Rozbruch said.

SF-36 scores improved for all categories.

"None of the patients had undergone ankle fusions," he said. "All patients objectively state that they are happy that they underwent this procedure, and our impression is that these clinical results, in fact, improve over time."

Rozbruch added that the exact mechanism for cartilage regeneration with these devices is unclear. In addition, surgeons cannot always see radiographic improvement in the joint space, and the roles of adjuvant procedures and ankle motion remain unclear.

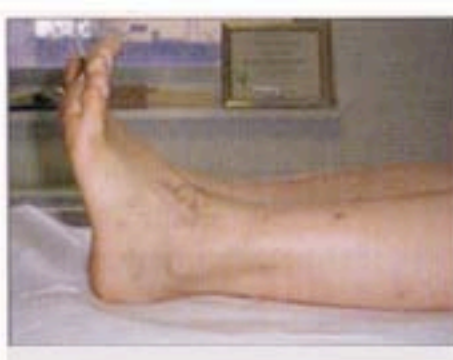"We have plans to do a prospective study and actually do MRI with cartilage sequencing before and after [fixation] to be a little bit more objective," Rozbruch said.

### For more information:

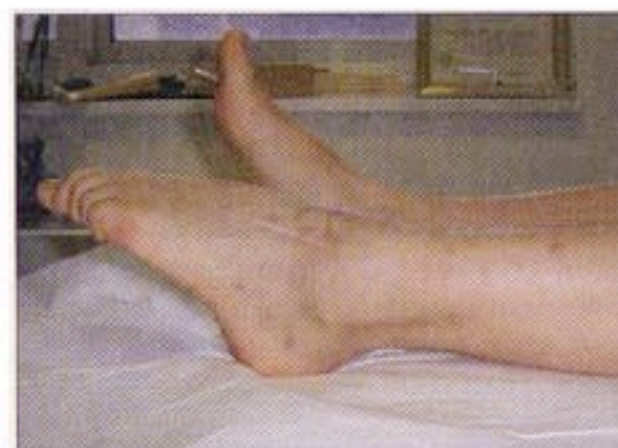S. Robert Rozbruch, MD, can be reached at the Hospital for Special Surgery, 535 E. 70th St., New York, NY 10021; 212-606-1415; e-mail: rozbruchs@hss.edu. He receives research support from Smith & Nephew and is a paid consultant for SBI. He also has a financial relationship with Biomet.

### Reference:

Rozbruch SR. Ankle joint distraction using the Ilizarov fixator: A study of outcome. Presented at the American Orthopaedic Foot and Ankle Society 23rd Annual Summer Meeting, July 13-15, 2007, Toronto.



The patient maintained range of motion, as seen in this image.



Another image of the patient's outcome.